

## Biliary stent

Shunsuke Sugawara, MD

Department of Diagnostic Radiology, National Cancer Center Hospital, Japan

### 1. Concept

The purpose of biliary stenting is to reproduce normal bile juice flow with expansion of biliary stricture and to relieve patients from restrictions caused by drainage tubes. Biliary stenting is commonly used for patients with malignant biliary stricture in palliative care setting. Retrograde endoscopic access via papilla of Vater is widely performed for biliary stenting, especially for simple stricture of the common bile duct (CBD). However, percutaneous access is required for complicated cases such as multiple biliary strictures in hilum or postoperative cases with choledocho-/hepaticojejunostomy.

### 2. Indications

- (1) Unresectable malignant biliary stricture\*
- (2) Removal of PTBD tube is clinically meaningful
- (3) No stricture in duodenum and lower intestine
- (4) No uncontrollable coagulopathy

\*In case of benign stenosis, metallic stent placement is not allowed except a retrievable or biodegradable stent.

### 3. Procedures (Steps and Tips)

#### 3-1. Simple stenosis

**Step 1:** PTBD (Percutaneous transhepatic biliary drainage)

The PTBD route with acute angle such as B2 and B7 access should not be used to avoid technical difficulties in subsequent catheter manipulations.

**Step 2:** Drainage and contrast injection

## 15. Biliary stent (Shunsuke Sugawara, MD)

Decompression of dilated bile duct is important to visualize the exact anatomy of biliary system and the details of stricture site. We should keep in mind that contrast injection with high pressure can cause septic shock.

### Step 3: Insertion of an angiographic sheath (Figure 1)

Using an angiographic sheath is very useful to keep the route between skin puncture point and biliary system, and to perform repeated injection of contrast.

### Step 4: Crossing of stricture

A seeking catheter (multipurpose type) (4-6Fr) and a hydrophilic guidewire are the key combination to success. The technical tip is not only pushing and pulling but also rotating.

### Step 5: Contrast injection into the lower biliary system and intestine (Figure 2).

In this process, the length and feature of the stricture must be evaluated, and the function of papilla of Vater / duodenum / lower intestine must also be observed. The actual length of stricture should be measured using a guidewire or a catheter.

### Step 6: Exchange of guidewire (from hydrophilic to non-hydrophilic one)

Seeking catheter is advanced into the duodenum in order to perform exchange of guidewire. To avoid accidental removal of guidewire, guidewire should be exchanged to a stiff and non-hydrophilic coated one. A stiff guidewire also provides stability during stent deployment.

### Step 7: Taking reference images with contrast

The reference images acquired should be in the same direction as the image used during stent deployment.

### Step 8: Selection of stent (bare / covered, length and diameter).

Generally, covered stents have longer patency rate. However, bigger access route and longer landing zone are needed to insert covered stents. The decision should be made with deep considerations including technical factors, invasiveness and also the patient's life expectancy etc.

### Step 9: Insertion of the stent delivery system beyond the stricture (Figure 4)

Delivery system is advanced beyond the stricture over the guidewire. When the stricture is very narrow and tight, predilatation with a balloon catheter (6-8mm in

## 15. Biliary stent (Shunsuke Sugawara, MD)

diameter) can be performed.

### Step 10: Decision on point for stent deployment

The point for stent deployment must be decided with careful consideration about foreshortening of the stent, especially when woven stents are used.

### Step 11: Stent deployment (Figure 5)

The most important technical issue is to keep the key marker of stent at the same point on by using real-time fluoroscopy during stent deployment.

### Step 12: Removal of the stent delivery system

Contrast is injected via the angiographic sheath and position of stent is confirmed if it is placed at the appropriate position. After that, the angiographic sheath is removed.

### Step 13: Insertion of a drainage tube (safety tube) and removal of guidewire

During processes between step 4 and step 13, the guidewire must be kept in position. Safety tube should be placed proximal to the stent.

### Step 14: Removal of safety tube

Safety tube is generally removed a few days after stent placement. Safety tube should be clamped for a few days and it should be checked that the general condition and laboratory data are stable. Just before the removal of safety tube, flow of contrast to the duodenum is evaluated.

## 3-2. Complicated stenosis (Bismuth type III/IV)

### Step 1: Technique of multiple stents placement

The crucial point of decision is "Which branches should be preserved, and which branches should be sacrificed". Volume of each segment and patency of portal veins are assessed in deciding the technique of stent placement.

### Step 2-10: (Same as Step 2-10 in simple stenosis)

### Step 11: Insertion of multiple stent delivery systems (Figure 7)

All stent delivery systems must be set up at the appropriate positions before deploying any stent especially when stents are placed side-by-side (parallel formation).

## 15. Biliary stent (Shunsuke Sugawara, MD)

### Step 12: Stent deployment with parallel formation (Figure 8)

There are other techniques of multiple stents placement such as Y-formation and T-formation. Parallel formation is much easier to perform re-intervention.

### Step 13: Insertion of drainage tubes (safety tube) (Figure 9)

When the procedures were well performed with bare stents, placing one safety tube is enough.

### Step 14: Removal of the safety tube

Removal of the safety tube must be performed after confirmation of good flow of contrast from proximal portion to duodenum through the stent. This is best done a day or two days after stenting.

## 4. Special issues

### #1 Bare stent versus covered stent

There have been several reports comparing stent patency rate between bare stent and covered stent. Based on these reports, the patency rate may be longer in covered stent. However, covered stent needs bigger access route and longer landing zone. It also has higher risk of stent migration and obstructing other branches. Therefore, the selection should be considered based on not only technical factors, but also the performance status and life expectancy of the patient. In patients with poor prognosis of less than a few months, usually there is no difference in clinical outcome between both stents.

### #2 Indication for patients with massive ascites

The risk of bleeding and biliary peritonitis must be considered in biliary stenting for a patient with massive ascites. The easiest method is performing all biliary procedures after complete ascites drainage. On the other hand, there is risk of bleeding and leakage of bile juice caused by keeping percutaneous tubes through ascites or accidental withdrawal of catheter and/or guidewire. Therefore, if all procedures and removal of all tubes are completed in one session, and tract embolization with coils/gelatin sponge were completely performed, biliary stenting can be carried out without complications (Figure 10)

## 15. Biliary stent (Shunsuke Sugawara, MD)

### #3 Stent placement across the papilla of Vater (Figure 11)

Manipulation of guidewire or catheter can cause transient edematous change in papilla of Vater, resulting in temporary obstruction of contrast flow. This may mimic obstruction caused by tumour. Thus, the function of papilla of Vater must be observed carefully prior to guidewire/catheter manipulation in this area. In cases where the papilla of Vater is involved and obstructed by tumour, stent placement across the papilla of Vater should be performed. The length of stent protruding into the duodenum should not be too long because the edge of the stent abutting the intestinal wall may injure the wall, leading to ulceration and bleeding.

Sometimes, stent placement across the papilla of Vater causes pancreatitis. However, in most of the case, it disappears with medical treatment.

### #4 Combination with balloon dilatation

When the stricture is very tight, pre or post balloon dilatation is very useful. Balloon dilatation before stenting (Pre-dilatation) is also useful to know the characteristics of stricture (length, hardness, mobility, etc). Balloon dilatation after stenting (Post stenting) is useful to achieve the full expansion of the stent and to affix the stent firmly to the inner wall of the bile duct. When post balloon dilatation is needed for a stent that has potential of foreshortening (woven stent), the first dilatation should be performed at the narrowest (not expanded) portion of the stent. In this manner, the stricture site would be covered by the stent even if the stent has foreshortened (Figure 12).

## References

- 1) Isayama H, et al: A prospective randomized study of "covered" versus "uncovered" diamond stents for the management of distal malignant biliary obstruction. *Gut* 53 : 729 - 734, 2004.
- 2) Soderlund C, Linder S: Covered metal versus plastic stents for malignant common bile duct stenosis : a prospective, randomized, controlled trial. *Gastrointest Endosc* 63 : 986 - 995, 2006.
- 3) Inal M, et al: Percutaneous placement of biliary metallic stents in patients with

15. Biliary stent (Shunsuke Sugawara, MD)

malignant hilar obstruction: unilobar versus bilobar drainage. *J vasc Interv Radiol* 14 : 1409 - 1416, 2003.

- 4) Brountzos EN, et al: A survival analysis of patients with malignant biliary strictures treated by percutaneous metallic stenting. *Cardiovasc Intervent Radiol* 30 : 66 - 73, 2007.
- 5) Rerknimitr R, et al: Outcome of self-expandable metallic stents in low-grade versus advanced hilar obstruction. *J Gastroenterol Hepatol* 23 : 1695 - 1701, 2008.

Figure 1: Insertion of angiographic sheath

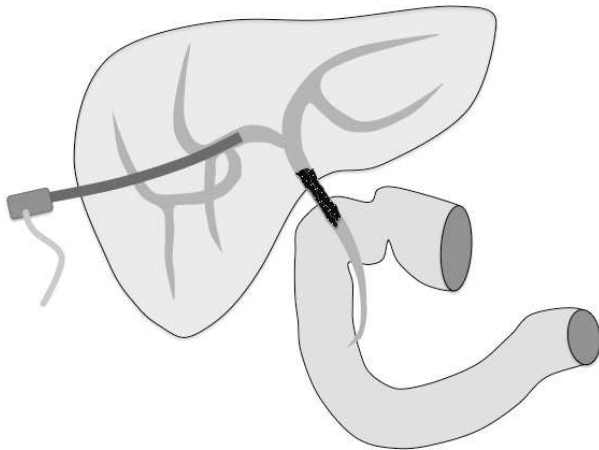
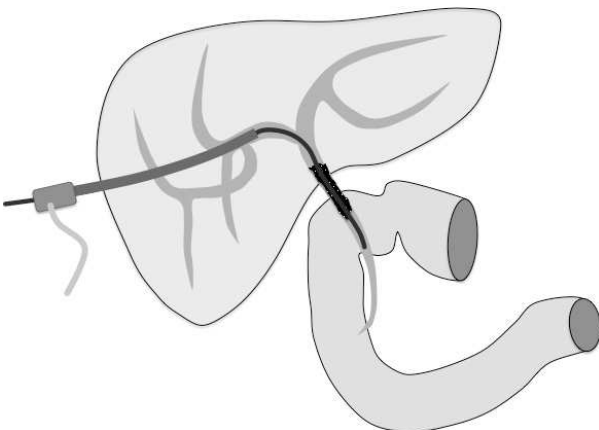


Figure 2: Crossing the stricture



15. Biliary stent (Shunsuke Sugawara, MD)

Figure 3: Contrast examination of lower biliary system and intestine

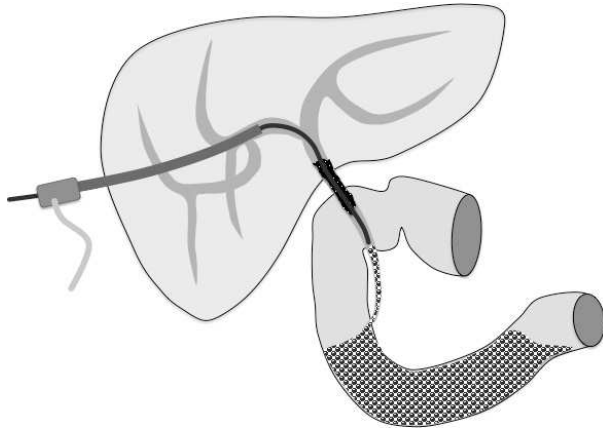


Figure 4: Insertion of stent delivery system beyond the stricture

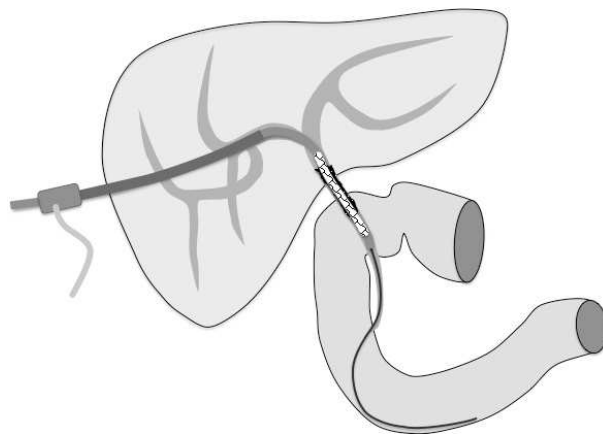
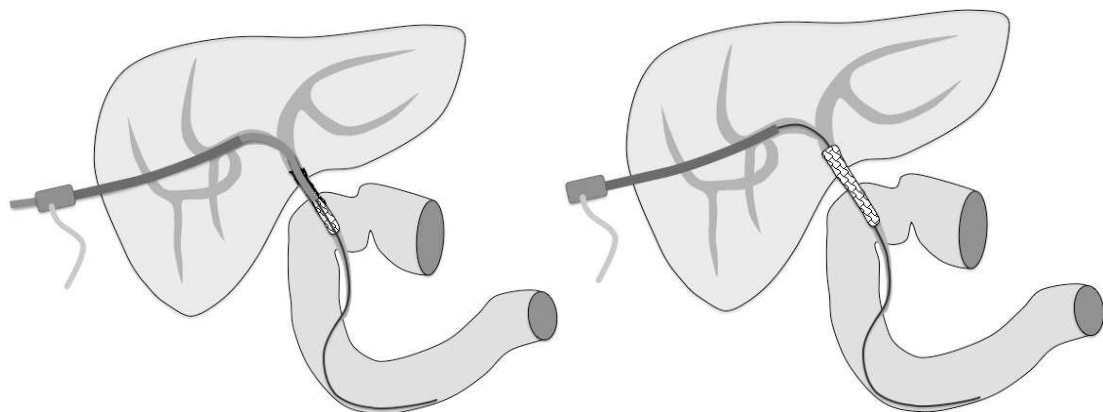


Figure 5: stent release



15. Biliary stent (Shunsuke Sugawara, MD)

Figure 6: placement of safety tube

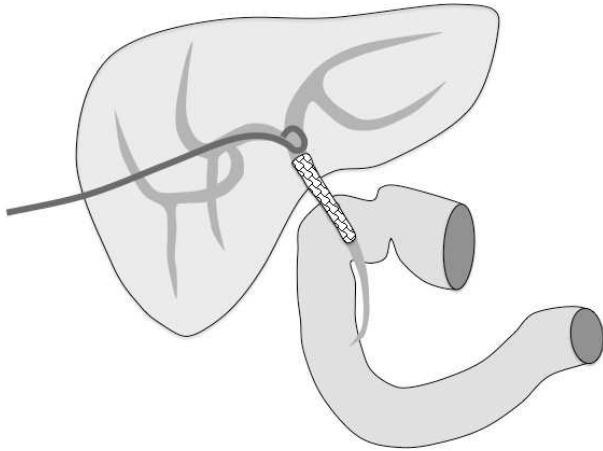


Figure 7: Parallel insertion of stent delivery systems

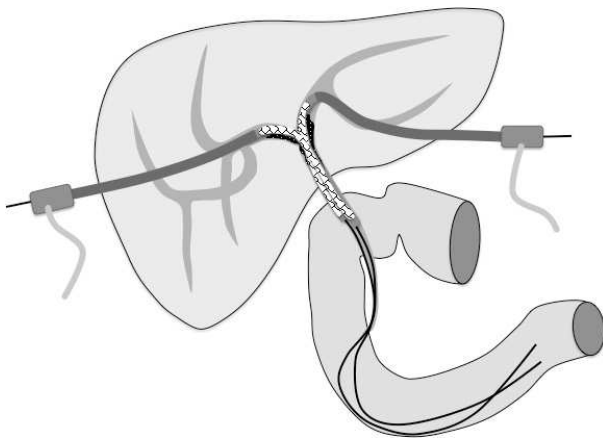
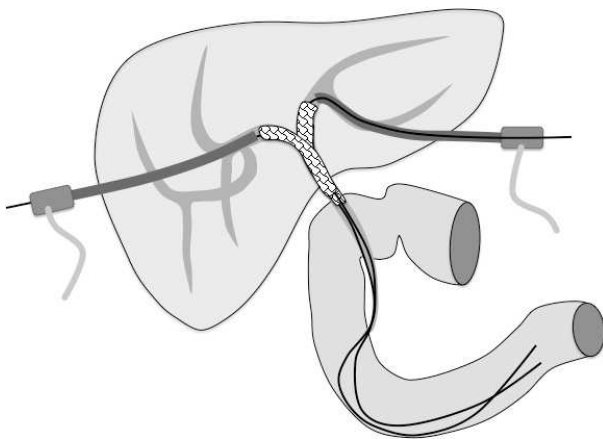


Figure 8: Stent release (Parallel formation)





15. Biliary stent (Shunsuke Sugawara, MD)

Figure 9: Placement of Safety tubes

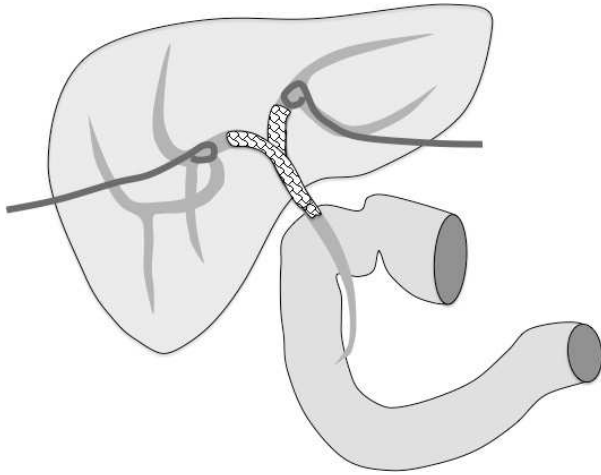


Figure 10: Tract embolization

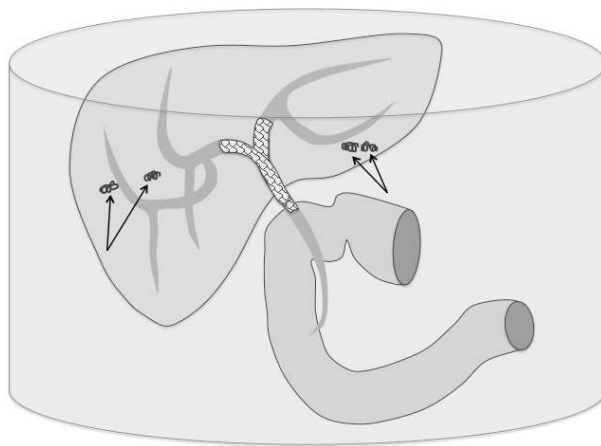
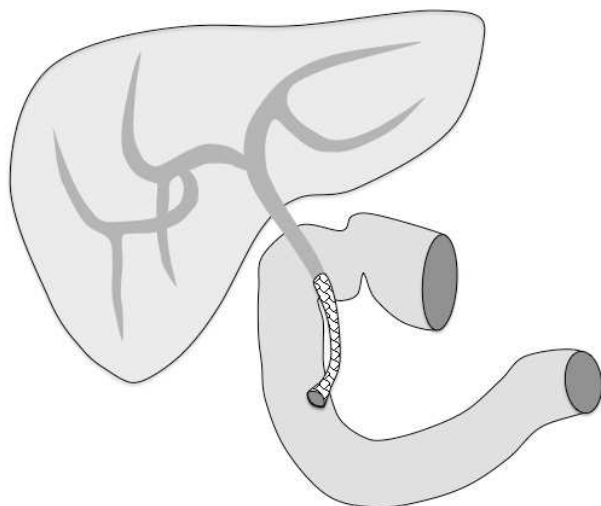


Figure 11: Stent placement crossing the papilla of Vater



15. Biliary stent (Shunsuke Sugawara, MD)

Figure 12: Foreshortening of stent with balloon dilatation

